Computer Methods and Programs in Biomedicine 211 (2021) 106382

Contents lists available at ScienceDirect

Computer Methods and Programs in Biomedicine

journal homepage: www.elsevier.com/locate/cmpb

Lightweight deep neural networks for cholelithiasis and cholecystitis detection by point-of-care ultrasound

Chih-Jui Yu[a], Hsing-Jung Yeh[a], Chun-Chao Chang[a,b,1,*], Jui-Hsiang Tang[a], Wei-Yu Kao[a,b], Wen-Chao Chen[a], Yi-Jin Huang[c], Chien-Hung Li[c], Wei-Hao Chang[c], Yun-Ting Lin[c], Herdiantri Sufriyana[d,f], Emily Chia-Yu Su[d,e,1,**]

[a] *Division of Gastroenterology and Hepatology, Department of Internal Medicine, Taipei Medical University Hospital, Taipei 110, Taiwan*
[b] *Division of Gastroenterology and Hepatology, Department of Internal Medicine, School of Medicine, College of Medicine, Taipei Medical University, Taipei 110, Taiwan*
[c] *Acer Value Lab Advanced Tech Business Unit, Acer Incorporated, New Taipei City 221, Taiwan*
[d] *Graduate Institute of Biomedical Informatics, College of Medical Science and Technology, Taipei Medical University, Taipei 110, Taiwan*
[e] *Clinical Big Data Research Center, Taipei Medical University Hospital, Taipei 110, Taiwan*
[f] *Department of Medical Physiology, Faculty of Medicine, Universitas Nahdlatul Ulama Surabaya, Surabaya 60237, Indonesia*

ARTICLE INFO

Article history:
Received 6 February 2021
Accepted 24 August 2021

Keywords:
Ultrasound
Abdomen
Computer-aided diagnosis
Machine learning
Neural network
Pattern recognition

ABSTRACT

Background and objective: Emergency physicians (EPs) frequently deal with abdominal pain, including that is caused by either gallstones or acute cholecystitis. Easy access and low cost justify point-of-care ultrasound (POCUS) use as a first-line test to detect these diseases; yet, the detection performance of POCUS by EPs is unreliable, causing misdiagnoses with serious impacts. This study aimed to develop a machine learning system to detect and localize gallstones and to detect acute cholecystitis by ultrasound (US) still images taken by physicians or technicians for preliminary diagnoses.
Methods: Abdominal US images (> 89,000) were collected from 2386 patients in a hospital database. We constructed training sets for gallstones with or without cholecystitis (N = 10,971) and cholecystitis with or without gallstones (N = 7348) as positives. Validation sets were also constructed for gallstones (N = 2664) and cholecystitis (N = 1919). We applied a single-shot multibox detector (SSD) and a feature pyramid network (FPN) to classify and localize objects using image features extracted by ResNet-50 for gallstones, and MobileNet V2 to classify cholecystitis. The deep learning models were pretrained using the COCO-2017 and ILSVRC-2012 datasets.
Results: Using the validation sets, the SSD-FPN-ResNet-50 and MobileNet V2 achieved areas under the receiver operating characteristics curve of 0.92 and 0.94, respectively. The inference speeds were 21 (47.6 frames per second, fps) and 7 ms (142.9 fps).
Conclusions: A machine learning system was developed to detect and localize gallstones, and to detect cholecystitis, with acceptable discrimination and speed. This is the first study to develop this system for either gallstone or cholecystitis detection with absence or presence of each one. After clinical trials, this system may be used to assist EPs, including those in remote areas, for detecting these diseases.
© 2021 Elsevier B.V. All rights reserved.

Abbreviation: Acc., accuracy; AUC, area under the receiver operating characteristic curve; Avg. prec., average precision; CI, confidence interval; CNN, convolutional neural network; COCO, common objects in context; CT, computed tomographic; ED, emergency department; EP, emergency physician; FP, false positives; FPN, feature pyramid network; FN, false negatives; ILSVRC, ImageNet large scale visual recognition challenge; MCC, Matthew's correlation coefficient; POCUS, point-of-care ultrasound; PPI, pixels per inch; PPV, positive predictive value; Prec., precision; ROC, receiver operating characteristic; SD, standard deviation; Sens., sensitivity; Spd., speed; Spec., specificity; SSD, single-shot multibox detector; TP, true positives; TN, true negatives; US, ultrasound.

* Corresponding author at: Division of Gastroenterology and Hepatology, Department of Internal Medicine, Taipei Medical University Hospital, 252 Wu-Xing St., Taipei 11031, Taiwan.

** Corresponding author at: Graduate Institute of Biomedical Informatics, College of Medical Science and Technology, Taipei Medical University, 250 Wu-Xing St., Taipei 11031, Taiwan.

E-mail addresses: 143001@h.tmu.edu.tw (C.-J. Yu), g658105003@tmu.edu.tw (H.-J. Yeh), chunchao@tmu.edu.tw (C.-C. Chang), 151002@h.tmu.edu.tw (J.-H. Tang), 121021@tmuh.org.tw (W.-Y. Kao), 143007@h.tmu.edu.tw (W.-C. Chen), kelly.huang@acer.com (Y.-J. Huang), Ivan.Li@acer.com (C.-H. Li), Martin.Chang@acer.com (W.-H. Chang), yuntinglin26@gmail.com (Y.-T. Lin), herdiantrisufriyana@unusa.ac.id (H. Sufriyana), emilysu@tmu.edu.tw (E.C.-Y. Su).

[1] These authors contributed equally to this work.

https://doi.org/10.1016/j.cmpb.2021.106382
0169-2607/© 2021 Elsevier B.V. All rights reserved.

1. Introduction

Abdominal pain is the most frequent symptom dealt with emergency physicians (EPs) [1]. Right upper quadrant pain is most commonly associated with hepatobiliary pathology that requires point-of-care ultrasound (POCUS) as first-line imaging to guide EP decisions for recommending either medical or surgical procedures [2]. Patients who were given POCUS by EPs had a shorter length of stay in the emergency department compared to those referred to other radiological imaging (309 ± 30 vs. 433 ± 50 min; $p < 0.001$), among which 43% subsequently received a cholecystectomy [3]. However, a previous study also demonstrated that the length of stay was even longer for patients who underwent POCUS and who were discharged but asked to return to the hospital for other radiological imaging (968 min, 95% confidence interval [CI] 774 to 1110 min) [3]. That study pointed out poor sensitivities of POCUS by EPs in detection of gallstones (0.55, 95% CI 0.40 to 0.70) and gallbladder wall thickening (0.18, 95% CI 0.06 to 0.29). The latter condition may refer to acute cholecystitis. Although a cholelithiasis diagnosis is quite straightforward by ultrasound (US), diagnosing acute cholecystitis is more complicated [4]. More misdiagnoses of acute cholecystitis were attributed to US ($n = 8/14$, 57.14%) compared to computed tomographic (CT) scans, resulting in overcall ($n = 3/8$, 37.50%) and undercall ($n = 5/8$, 62.50%) of cholecystectomies [5]. In another study, from five patients with gallbladder edema misdiagnosed as cholecystitis, two died due to liver failure post-cholecystectomy, while acute cholecystitis would not have occurred to another seven patients had they not undergone the procedure [6]. In all of the misdiagnosed cases, the contributing factor was a failure to identify gallbladder wall thickening in the US examination [5,6].

The prevalence of gallstones or cholelithiasis ranges 5 to 20% worldwide [7]. The mechanisms of the disease are associated with diabetes mellitus type 2, obesity, and metabolic syndrome [8]. Gallstones may block the cystic duct leading to acute cholelithiasis among which 95% of patients had gallstones and needed a cholecystectomy [9]. The remaining patients were suffering from acute acalculous cholecystitis and needed a percutaneous cholecystostomy [10]. Although the timing is still being debated, an early cholecystectomy within 24 h of hospital admission was preferred based on a systematic review [11]. This argues for an immediate diagnosis of acute cholecystitis, that requires EP skill in interpreting POCUS images [12]. However, although POCUS by EPs is an urgent need, misdiagnoses cannot be tolerated since these causes longer length of stay [3], either overcall or undercall of cholecystectomies [5], and preventable deaths [6].

The accuracy of POCUS is widely diverse across EPs and non-radiologists. Compared to trained radiologists, surgeons can detect gallstones with an accuracy of 94.4% (95% CI 90.0 to 96.9) and surgeon-performed POCUS had strong agreement with radiologists (Cohen's kappa = 0.88) [13]. Although one study showed that EP-performed POCUS to detect gallstones was comparably as high as radiologists (sensitivity 0.93, 95% CI 0.82 to 0.97; Cohen's kappa = 0.88) [14], the performance in another study was far poorer (sensitivity 0.55, 95% CI 0.40 to 0.70) [3]. In addition, that previous study [14] also demonstrated that EP-performed POCUS to detect gallbladder wall edema was poor in terms of both sensitivity (0.40, 95% CI 0.14 to 0.73) and the positive predictive value (PPV; 0.33, 95% CI 0.11 to 0.65), and this had minimal agreement with radiologists (Cohen's kappa = 0.34). From those studies, the training level of EPs with good accuracy was higher than the level of those with poor accuracy. Meanwhile, a previous study in China described that < 20% of EPs had formal training in POCUS [15]. This indicates that the operator-dependent accuracy of POCUS needs to be addressed. In addition, different from cholelithiasis, US is not the best imaging tool for acute cholecystitis; however, easy access and low cost justify its use resulting in it being recommended as a first-line test for acute cholecystitis [4,16].

Applications of machine learning, including deep learning, have emerged for US applications to address operator-dependent limitations [17,18]. In gastroenterology, it is widely used for diagnoses and prognoses, most likely for applying deep-learning techniques to imaging data [19]. This was used for segmentation of gallstones on CT images with an accuracy of 90.8% [20]. Automated segmentation was also applied to US images with average precisions of 86.01% and 79.81% for segmenting gallbladder and gallstones, respectively [21]. However, the accuracy of diagnoses does not always mean better clinical efficacy, because diagnosing gallstones alone is not the bottleneck. Improvements in both accuracy and reliability of POCUS are needed to detect acute cholecystitis with or without cholelithiasis or gallstones.

Deep learning for medical image processing widely applied convolutional neural network (CNN) algorithms, particularly pre-trained CNN models including those with VGG19, ResNet50 V2, MobileNet V2, Xception, and Inception V2 algorithms [22]. These were then retrained at the top layer of neural network using medical images of interest. The first three algorithms won the ImageNet Large-Scale Visual Recognition Challenge (ILSVRC) in 2014, 2014, and 2015, of which ResNet50 V2 and MobileNet V2 were developed to decrease inference times and reduce network weights of VGG19 [23]. ResNet-50 was developed to pursue better predictive performance with deeper layers but easier training process. Other models were also developed for the same purpose [24,25], which were Inception V1, V2, and V3, of which Inception V2 was the best network architecture in term computational speed and efficiency. Inception v3 has different parameters for training but the same architecture as V2. Since our study explored the best architecture, we only claimed using Inception V2. With a similar network size to Inception v3, Xception algorithm was also developed to improve the performance using a depth-wise separable convolution [26]. Using the same technique, the MobileNet V1 and V2 models were developed at the tip of the algorithm evolution for computational speed and efficiency up to the beginning of this study [27,28]. Since CNN algorithm development is extremely fast, there are more algorithms with better performance and computational speed and efficiency up to the end of this study. Yet, we only used three algorithms which were already mature for application in medicine within a continuum of tradeoff between predictive performance (i.e. ResNet50 V2) and computational speed and efficiency (i.e. MobileNet V2), while Inception V2 is a balance tradeoff between those algorithms.

In this study, we needed algorithms that considered computational efficiency since US is a real-time examination which needs an agile detection model. Hence, we applied the single-shot multibox detector (SSD) and feature pyramid network (FPN) algorithms on our computationally-efficient CNN detection models. For application in medicine, the SSD was used on ResNet-50 for coronary calcium detection on CT images [29]. Meanwhile, the MobileNet V2 model was used for real-time detection of the aortic valve in echocardiography [30]. We found a couple of previous studies that applied deep learning for gallstones but none for cholecystitis. The first study developed a YOLO-v3 model that was intended to accurately detect gallstones from CT images faster on average than experienced doctors (25 to 35 s) [31]. A second study developed a MobileNet V2 model to detect gallstones from CT images using mobile devices [20]. The goals of our study were to develop a precise and agile prediction model for detecting and localizing gallstones with or without cholecystitis, and a sensitive and precise prediction model for detecting cholecystitis with or without gallstones, by utilizing US still images in a mobile device.

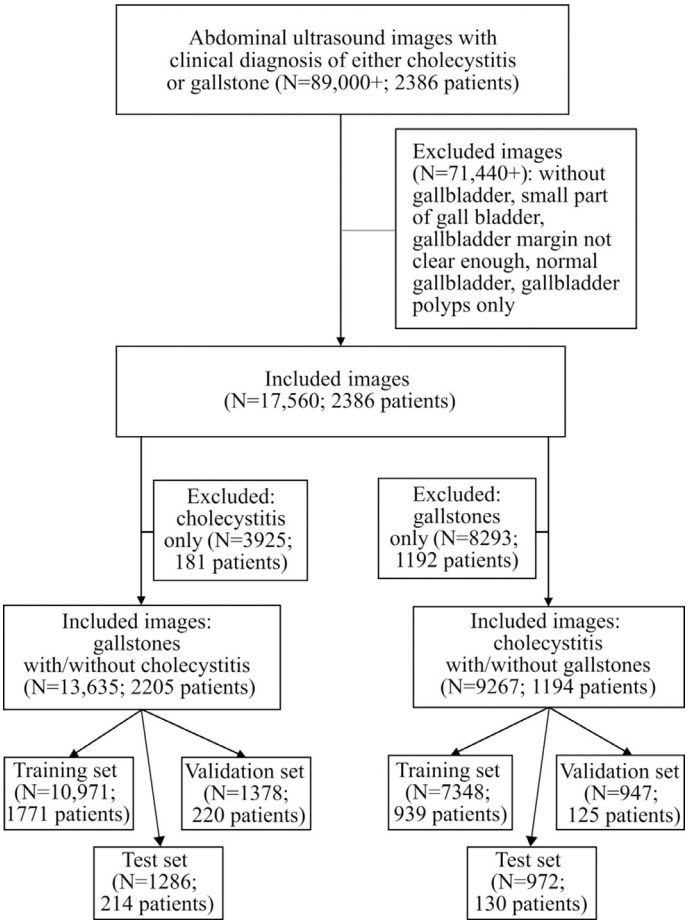

Fig. 1. Flowchart of selection criteria and data partitioning. The flowchart is mainly described in term of images instead of patients, but the numbers of both images (*N*) and patients are given.

2. Material and methods

2.1. Dataset

This study was divided into two parts: gallstone detection and localization, and cholecystitis detection. From the Department of Gastrointestinal Ultrasound Image Database of Taipei Medical University Hospital, we included over 89,000 abdominal US images taken from 2386 patients using curvilinear transducers (Fig. 1). Informed consent for this study was waived by Taipei Medical University Joint Institutional Review Board (TMU-JIRB; No. N201803006). The images have been de-identified before being stored into the image database. Image retrieval from this database was conducted by several medical doctors using keywords of gallstones and cholecystitis. Two medical doctors manually label the images. These needed to meet the following four criteria to be used for our study. First, there had to be a gallbladder in the image. Second, if the gallbladder resided on the image boundary, the non-visible part must be less than 1/3 of the gallbladder. We let a small part of the gallbladder to be non-visible to approach a real-world situation in which an EP cannot capture a US image that completely covers a gallbladder. Third, there must be either a gallstone or cholecystitis or both in the image. Fourth, the image had to be clear enough (not blurred or obscure). Definitions of cholecystitis and cholelithiasis were based on abdominal ultrasonographic diagnoses by physicians and the above image diagnostic criteria. Finally, 17,560 images were included. We expected the detection models to learn the hallmarks of either gallstones or cholecystitis with absence or presence of each one. The image format was jpeg. We removed the text appearing on the US images before model training. Other details in data preprocessing is also described (see Supplemental Materials).

Note that we did not include images with neither a gallstone nor a cholecystitis. A previous study already developed an automated segmentation of US images with acceptable average precision for segmenting gallbladder and gallstones [21]. We focused on another bottleneck problem which was to detect gallbladder wall edema. This was poor in terms of both sensitivity and PPV, and EP-performed POCUS for that condition had minimal agreement with radiologists [14]. To solve this problem, we trained models that differentiated a gallstone, a cholecystitis, and both using US images. Acute cholecystitis is one that causes gallbladder wall thickening [32]. This condition is also a relatively common disease, accounting for 5% of the patients arriving to the emergency department with abdominal pain and 3 to 9% of hospital admissions, and it is caused by gallstones in more than 90% of patients [33]. Therefore, our models should be preceded with clinical assessment to subsequently exclude other causes of abdominal pain and gallbladder wall thickening [34]. Our models also should be combined with previous segmentation models that already have an acceptable negative predictive value.

2.2. Pretrained datasets

Our goal was to assist EPs with no formal training in interpreting POCUS images, to perform examinations with similar accuracy to trained radiologists. Convolutional neural network (CNN) algorithms recently contributed to great success with machine learning applications for medical imaging, especially those utilizing pretrained CNN models (transfer learning) [22,35]. This is because training CNN models from scratch requires a large image collection and computationally expensive image processing. However, our training datasets were relatively small compared to those for object detection in computer vision. To deal with this problem, we used pretrained datasets which were from Common Objects in Context (COCO)-2017 [36], and ImageNet Large Scale Visual Recognition Challenge (ILSVRC)-2012 [37]. These pretrained models were then fine-tuned using our datasets for, respectively detecting and localizing gallstones, and for detecting cholecystitis. Fine-tuning was conducted by retrain the last fully-connected layer. This procedure is intended to solve issue of different data distribution between natural and medical images. The convergence speed of transfer learning is also faster than that of training from scratch. This procedure is a common practice for CNN applications in medicine. CNN learning for everyday-object image classification was successfully used for breast tumor image classification [38,39]. A faster region-based CNN model had been pretrained on the COCO-2017 dataset and fine-tuned with 14,000 pediatric radiographs [40].

2.3. Deep-learning algorithms

Considering computational efficiency to provide an agile detection model for POCUS in this study, we applied the SSD and FPN algorithms on our CNN detection models. The SSD algorithm directly sampled grids of an input image and assigned these grids to multiple bounding boxes in single instead of two stages [41,42]. The SSD is generally faster but has poorer accuracy, particularly for small objects [43]. Hence, we also applied the FPN algorithm that produces multiscale versions of an image [44]. This made the features semantically strong on all scales. Instead on the top of the VGG-16 architecture [45], we applied the SSD-FPN on the top of the ResNet-50 architecture for detecting and localizing gallstones

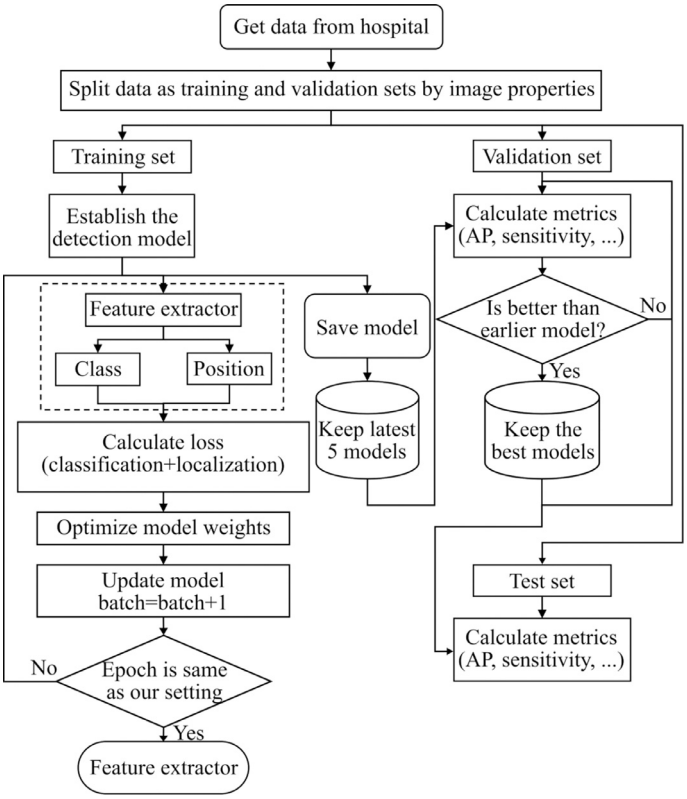

Fig. 2. Systematic architecture of the proposed study. Establishing a detection model means constructing the model architectures: (1) ResNet-50, single-shot multibox detector (SSD), and feature pyramid network (FPN) for gallstone detection and localization; and (2) MobileNet V2 for cholecystitis detection (see Fig. 3). Features were extracted by ResNet-50 and MobileNet V2. Then the features were fed to the SSD and FPN to determine the class and the position of gallstones. AP, average precision.

(Fig. 2). This is because ResNet-50 was developed to ease the training process of a deep neural network [46]. Meanwhile, we applied MobileNet v2 without the SSD-FPN for detecting cholecystitis (Fig. 3). These algorithms were selected after considering a balance of performance, speed, and computational resources needed to apply the models (i.e., mobile devices).

After obtaining data from the hospital (Fig. 2), the dataset was split according to a ratio of patients by 80:10:10, respectively into training, validation, and test sets. We separated the dataset based on several data properties to prevent bias, including single or multiple stones, a significant acoustic shadow or not, a cross mark upon at stone or gallbladder, US image machine source (Toshiba/BenQ), size of the stone, and severity of cholecystitis (e.g., wall thickening, triple-layer sign). For data augmentation, we used random crop, random horizontal flip, and random color adjustment. The image data were preprocessed by subtracting the ImageNet mean value (R: 123.68, G: 116.779, B: 103.939) from all RGB values of the input images. All RGB values were scaled to a range of -1 to 1.

We applied a grid search to tune some of the model parameters, while some of the other parameters followed the default setting based on the original publication of the selected algorithms. We compared several parameters for gallstone detection and localization, which consisted of the learning rate decay (cosine vs. exponential decay) and focal loss (alpha = [0.25, 0.5, 0.75]). Meanwhile, for cholecystitis detection, we compared the parameters of input size (224 × 224, 288 × 288, and 352 × 352), batch size (64 vs. 128), dropout keep probability (0.5 vs. 0.8), learning rate decay (constant vs. exponential decay), optimizer (RMSProp vs. Adam), and random color adjustment (without or with method). We used the average precision (%) to compare the parameters for gallstones, while cholecystitis was compared using the F1-score (%), precision (%), recall (%), and specificity (%); yet, we emphasized the algorithm selection by the F1-score considering a summarized measure for the calibration and discrimination power.

Beyond the compared parameters, we determined the following parameters. For gallstone detection, the picture input size was 320 × 320 pixels per inch (PPI). The batch size was 16. The weights were initialized by a zero-mean Gaussian distribution with a standard deviation (SD) of 0.01 and a weight decay of 0.0004. The learning rate was 0.0001, with decay for every 1500 steps, and a decay factor of 0.95. The focal loss applied a gamma of 2.0 for the classification task with a weight of 1.0, while smooth L1 was applied for the localization task with a weight of 1.0. The optimizer was stochastic gradient descent with momentum of 0.9. Meanwhile, for cholecystitis detection, the weights were initialized by the zero-mean Gaussian distribution with SD 0.09 and a weight decay of 0.00004. The learning rate was 0.0005. The loss metric was cross entropy. The decay factor was 0.9. The reasons for choosing the parameters are also described (see Supplemental Materials).

We trained the models of which the weights were optimized by losses of classification (gallstones and cholecystitis) and localization (gallstones). The training was complete if the number of epochs was the same as our setting; otherwise, the models were saved at the next epoch. Convergence of the training was confirmed if the validation loss was no longer decreasing. For each of the latest five models, we evaluated the models on the validation set and calculated the metrics. If a model was better than an earlier one, we kept that model. The deep learning platform was Tensorflow 1.11.0 and the GPU device was NVIDIA GeForce GTX 1080 Ti (with 11GB of VRAM).

2.4. Evaluation measures

Final evaluation was conducted using a test set. We plotted the receiver operating characteristic (ROC) curve and calculated the area under the ROC curve (AUC) as a measure of a model's performance on a classification task. Positive and negative were the highest scores of the predicted boxes of > 0.5 and ≤ 0.5, respectively. The ROC curve was obtained by plotting the true positive rate as a function of the false positive rate, or equivalently, sensitivity versus 1-specificity as the discrimination threshold of the binary classifier was varied. Each point on the ROC curve corresponded to the performance of the classifier at a specific choice of the classification threshold, i.e., at a particular choice of the trade-off between the true positive rate and false positive rate. The AUC is a useful summary statistic for comparing two ROC curves. The AUC ranges from 0.5 to 1, with 0.5 indicating a random predictor, and 1 indicating a perfect predictor.

Other metrics were also computed to allow more-comprehensive comparisons against previous studies. Sensitivity (Sens.) or recall and specificity (Spec.) measured how well the classifier detected gallstones and cholecystitis. In addition, overall accuracy (Acc.) and inference speed (Spd.) were incorporated to, respectively measure the correctness of the predicted results and the computational efficiency. To describe the proportion of correct results given a positive prediction, we computed the precision (Prec.) and F1-score. Matthew's correlation coefficient (MCC) was also computed considering both under- and over-prediction, to provide a complementary measure of the predictive performance. An MCC of 1 indicates a perfect prediction, an MCC of 0 indicates a completely random assignment, and an MCC of -1 indicates a perfectly reverse correlation. Eqs. (1) to (6) define these statistics, where *TP*, *TN*, *FP*, and *FN*, respectively denote the numbers of true

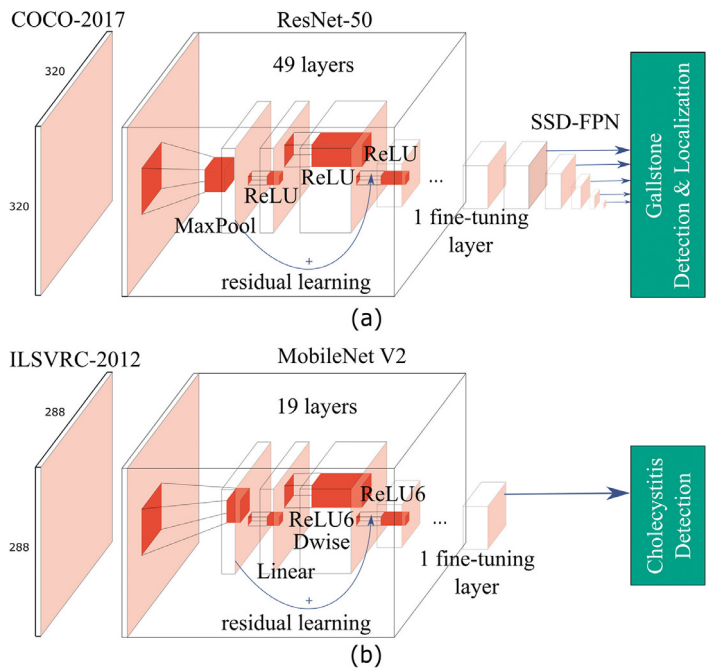

Fig. 3. Model architectures for detecting and localizing gallstones (a), and for detecting cholecystitis (b). The architectures of ResNet-50 and MobileNet V2 were simplified. Note that the MaxPool layer is included in the ResNet-50 but not in MobileNet V2. Only a linear function was applied for the first bottleneck layer in MobileNet V2 instead of the rectified linear unit (ReLU) nonlinearity in the corresponding layer of ResNet-50. ReLU6 and the depth-wise (Dwise) separable convolution layer were also applied in MobileNet V2. The upper part of ResNet-50 architecture was the single-shot multibox detector (SSD)-feature pyramid network (FPN). COCO, common objects in context; ILSVRC, ImageNet large-scale visual recognition challenge.

Table 1
Comparison of deep learning algorithms for detecting gallstones on the training set.

Algorithm	Precision		Agility		Chosen [a]
	Avg. prec. (%)	Rank	Spd. (ms)	Rank	
Faster R-CNN + ResNet-50	88.02	2	91	5	No
Faster R-CNN + Inception V2	88.23	1	43	4	No
SSD-FPN + ResNet-50	86.95	3	21	3	Yes
SSD-FPN + MobileNet V1	86.35	4	16	1	No
SSD + Inception V2	84.82	5	19	2	No
SSD + MobileNet V2	78.11	6	16	1	No

[a] Based on balanced rank of precision and agility.
Avg. prec., average precision; Spd., inference speed.

positives, true negatives, false positives, and false negatives:

$$Sensitivity\ or\ recall = \frac{TP}{(TP+FN)}, \tag{1}$$

$$Specificity = \frac{TN}{(FP+TN)}, \tag{2}$$

$$Accuracy = \frac{(TP+TN)}{(TP+TN+FP+FN)}, \tag{3}$$

$$Precision = \frac{TP}{(TP+FP)}, \tag{4}$$

$$F1 = 2\ \times \frac{Precision \times Recall}{(Precision + Recall)}, \text{and} \tag{5}$$

$$MCC = \frac{TP \times TN - FP \times FN}{\sqrt{(TP+FP)(TN+FN)(TN+FP)(TN+FN)}}. \tag{6}$$

3. Results

3.1. Comparisons of the predictive performance of gallstone detection and localization

Before being input to the SSD-FPN models, the features were extracted by ResNet-50 for detecting and localizing gallstones, and MobileNet V2 for detecting cholecystitis. The other models were Faster R-CNN with ResNet-50, Faster R-CNN with Inception V2, SSD-FPN with MobileNet V1, SSD with Inception V2, and SSD with MobileNet V2 (Table 1). In terms of the average precision, the SSD-FPN-ResNet-50 model was ranked in the 3rd position (86.95%) after the Faster R-CNN-ResNet-50 (88.23%) and Faster R-CNN-Inception V2 (88.02%). But, the model only needed 21 ms to detect gallstones, which was also ranked in the 3rd position after both SSD-FPN-MobileNet V1 and SSD-MobileNet V2 (16 ms), and SSD-Inception V2 (19 ms). Therefore, we chose the SSD-FPN with ResNet-50 based on comparisons with other models on the trade-off between accuracy and speed.

Applying the SSD-FPN-ResNet-50 algorithm with the best parameters (Table 2), the model for gallstone detection achieved an AUC of 0.92 (Table 3; Fig. 4a). Compared to those of the cholecystitis detection model, the sensitivity (92%), precision (93%), and

Table 2
Comparison of the SSD-FPN-ResNet-50 parameters for detecting gallstones on the training set.

Parameter	Avg. prec. (%)	Chosen
Decay		
Cosine	86.77	No
Exponential	87.31	Yes
Alpha		
0.25	86.86	No
0.5	86.93	No
0.75	87.21	Yes

Avg. prec., average precision.

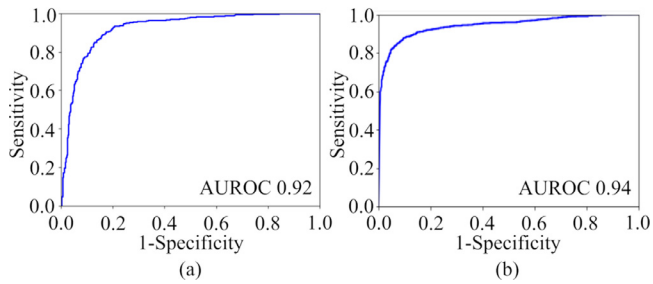

Fig. 4. Receiver operating characteristic curves for gallstone (a) and cholecystitis (b) detection. AUROC, area under receiver operating characteristic curve.

F1-score (92%) of the gallstone model were higher. Yet, the MCC for this model was lower (0.72 vs. 0.81) due to imbalanced classes (1286 positives, 73.7% vs. 459 negatives, 26.3%) compared to those of the cholecystitis detection model.

3.2. Comparisons of the predictive performance of cholecystitis detection

Before choosing the MobileNet V2 model for cholecystitis detection, we also compared two deep learning algorithms (Table 4). The MobileNet V2 model outperformed ResNet-50 in terms of the F1-score (91.39 vs. 87.88%), precision (93.55 vs. 87.83%), sensitivity (89.32 vs. 87.94%), and specificity (94.7 vs. 89.5%). A MobileNet model yielded small networks and also optimized the speed by latency restriction [27]; hence, the model uses 8 to 9 times less computational power. In MobileNet V2, thin bottleneck layers were added between the separable convolution blocks [28].

Applying the MobileNet V2 algorithm with the best parameters (Table 5), the model for cholecystitis detection achieved an AUC of 0.94 (Table 3; Fig. 4b). Compared to those of the gallstone detection model, the specificity (90%) and inference speed (7 ms; 47.6 fps) of the cholecystitis model were higher, with comparable accuracy (89%). Since the speed was inferred in a high-end computer, the model may take more time in low-end computer (i.e. no graphics processing unit or GPU). This model also achieved a higher MCC compared to that of the gallstone model (0.81 vs. 0.72) with a better balance of classes (972 positives, 55.7% vs. 773 negatives, 44.3%).

Table 4
Comparison of deep learning algorithms for detecting cholecystitis on the training set.

Algorithm	F1-score (%)	Prec. (%)	Sens. (%)	Spec. (%)
ResNet50	87.88	87.83	87.94	89.50
MobileNetV2	91.39	93.55	89.32	94.70

Prec., precision; Sens., sensitivity; Spec., specificity.

Table 5
Comparison of the MobileNet V2 parameters for detecting cholecystitis on the training set.

Parameter	F1-score (%)	Prec. (%)	Sens. (%)	Spec. (%)
Input size				
224 × 224	67.82	62.54	74.06	88.52
288 × 288	70.97	73.01	69.04	93.39
352 × 352	71.91	65.08	80.33	88.84
Batch size				
64	91.39	93.55	89.32	94.70
128	91.89	92.71	91.08	93.83
Dropout keep probability				
0.5	69.81	71.49	68.2	92.96
0.8	70.97	73.01	69.04	93.39
Learning rate decay				
Constant	91.74	94.05	89.54	94.36
Exponential decay	91.38	92.14	90.63	92.30
Optimizer				
RMSProp	93.06	94.1	92.05	94.25
Adam	92.62	93.65	91.61	93.82
Random color adjustment				
Without method	87.68	88.47	86.9	93.07
With method	88.51	89.07	87.96	93.40

Prec., precision; Sens., sensitivity; Spec., specificity.

4. Discussion

4.1. Comparison with previous studies

In this study, we achieved satisfactory performances for both gallstone and cholecystitis detection. The performance of the gallstone detection was higher than a model from a previous study using different dataset (79.81%) [21]. We could find no previous studies that developed an automated detection system for cholecystitis using US. Hence, we needed to compare our results to previous studies that evaluated predictive performances of either gallstone or cholecystitis detection by human-performed US.

A meta-analysis determined pooled sensitivities and specificities of surgeon-performed US to detect gallstones [47]. The pooled sensitivity was 96% (95% CI 93.4% to 97.9%), while the pooled specificity was 99% (95% CI 98.3% to 99.8%). The gold standard of diagnosis was the final discharge diagnosis either by a pathological examination or radiologist-performed US. The sensitivity (90.54%)

Table 3
Detection performances and the inference speed of gallstones and cholecystitis on the test sets.

AUC	TP	TN	FP	FN	Sens.	Spec.	Acc.	Spd.	Prec.	F1	MCC
Gallstones											
0.92	1179	370	89	107	0.92	0.81	0.89	21[a]	0.93	0.92	0.72
Cholecystitis											
0.94	852	699	74	120	0.88	0.90	0.89	7[b]	0.92	0.90	0.81

[a] ms (47.6 fps);
[b] ms (142.9 fps);
AUC, area under the receiver operating characteristic curve; TP, true positive; TN, true negative; FP, false positive; FN, false negative; Sens., sensitivity; Spec., specificity; Acc., accuracy; Spd., inference speed; Prec., precision; MCC, Matthew's correlation coefficient.

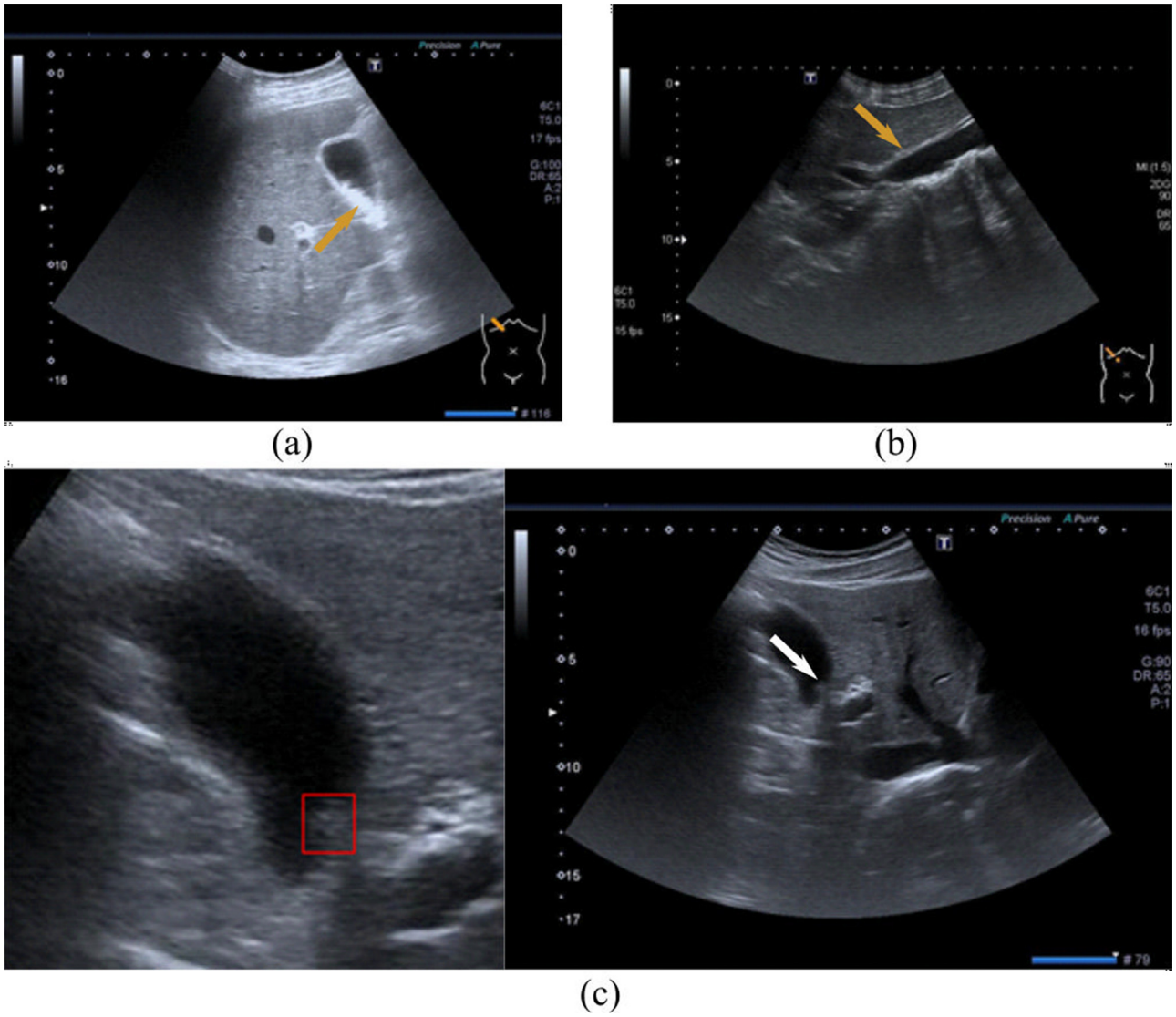

Fig. 5. Cases of erroneous detection. (a) In this picture, the gallstone margin is not clear enough, and the echogenicity is similar to the gallbladder wall. The machine learning false positively detected this picture as cholecystitis. (b) In this case, the arrow shows vascular lesion, but the machine learning detected this picture as a gallbladder. (c) On the left side of the picture, the reddish box includes one hyperechoic focus with an acoustic shadow detected as a gallstone, but in the raw data (right side picture, whitish arrow), we know that the shadow may have been caused by bowel gas or extra gallbladder tissue.

and specificity (89.1%) of our model for gallstone detection were still lower than those of surgeon-performed US.

Compared to those of a previous study that assessed EP-performed POCUS to detect gallstones (sensitivity 93%, 95% CI 82% to 97%; specificity 97%, 95% CI 94% to 99%), the model in this study achieved a comparable sensitivity, but not specificity. Yet, the EP-performed POCUS had varying results as shown by another study that assessed EP-performed POCUS to detect gallstones (sensitivity 55%, 95% CI 40% to 70%; specificity 92%, 95% CI 87% to 95%). Meanwhile, our model for cholecystitis detection had higher sensitivity (88.54%) and specificity (93.8%) compared to those pooled from previous studies. A meta-analysis showed a pooled sensitivity of 82% (95% CI 75% to 87%) and a pooled specificity of 81% (95% CI 73% to 87%) for acute cholecystitis by human-performed US (mostly by radiologists) [48]. This finding showed an improvement for the cholecystitis detection system using US, which is an added value compared to previous machine learning models that only focused on gallstone detection using US images without considering cholecystitis existence.

Computational efficiency is considered an issue for point-of-care diagnosis. This means less computational power and more speed. In the context of our study, these models would be applied on a mobile device which commonly has less computational power than a desktop computer. Speed in milliseconds really matters instead of that in seconds, because a US examination by an operator requires scanning over the abdomen of a patient by a real-time video. It commonly streams 24 frame (image) per second or minimum 41.67 ms of inference time. For illustration, a model that takes 5 s will need 250 times longer compared to that taking 20 ms. Therefore, this would not be possible to apply the model on POCUS had the inference time more than 41.67 ms for detecting both cholelithiasis and cholecystitis and localizing the gallstones.

4.2. Error case analysis

We conducted an error case analysis to learn the image features that might lead to false positives, when the ground truth was gallstones (Fig. 5a), normal (Fig. 5b), or cholecystitis (Fig. 5c). An image containing gallstones was falsely detected as cholecystitis (Fig. 5a). We found that gallstones showed unclear margins. We also noted that an image with neither gallstones nor cholecystitis was detected as a positive image (Fig. 5b); the vascular lesion

shown in this image was similar to the boundary of a gallbladder. This might have led the machine learning models to falsely detect the image as a positive one. A hyperechoic focus with an acoustic shadow in a cholecystitis image was also falsely detected as gallstones (Fig. 5c). The machine learning model was not aware of surrounding objects that may be considered by a US operator to confirm the hyperechoic focus with an acoustic shadow as a solid object.

More human-labeled US images are needed to determine which images might possibly be falsely detected for any objects of interest. Data augmentation in a balance between clear and unclear objects of interest may be needed to tell a machine learning model how to discriminate borderline cases. In our study, more gallstones with unclear margins should be augmented. Ground-truth regions of other objects are also needed to teach machine learning models to detect gallstones or cholecystitis by considering surrounding objects. This will also require more labeling by humans.

4.3. Clinical applications of this study

As expected, our model may address the problem of operator-dependent accuracy for future applications of POCUS to detect gallstones. This was achieved by automated detection with comparable sensitivity. Poor sensitivity of EP-performed POCUS can prolong the length of stay in the emergency department (ED) due to falsely discharged cases [3]. Therefore, the length of stay in EDs can be reduced, and patients can benefit from an early cholecystectomy [11]. In addition, since we can expect consistency of the detection performance by assisting EP-performed POCUS using our model, we can support EPs working in remote areas to conduct this first-line test in a telemedicine system. Yet, an EP should be able to capture 2/3 of part a gallbladder at minimum according to our criteria for the US image selection.

Another consideration worthy of note is our model development using US images included those containing both gallstones and cholecystitis. We developed the models to detect one of these conditions individually. This gives added value for future applications of US as a first-line test for acute cholecystitis with respect to the consistency of the detection performance. To the best of our knowledge, this is the first study to develop an automated detection system for cholecystitis using US.

4.4. Limitations of this study

We considered several limitations in this study. The gallbladder should be completely visible; otherwise, blood vessels may be falsely detected as the gallbladder wall, and thickening may also be overestimated. However, this is inevitable since we indeed let some US images incompletely covering a gallbladder to allow model application for less-experienced EPs. A precise estimation of wall thickening is also inevitable, since this condition is common due to an insufficient fasting time by patients. In addition, color Doppler US may help differentiate vascular lesions from the gallbladder wall.

This study also used still images instead of moving ones as the input for training the detection models. Small gallstones are difficult to discriminate from small gallbladder polyps. Changing the patient position will move the gallstones but not the polyps; thus, video input may improve the detection model in future studies. Nevertheless, although using still images, our models are possible to deploy for real-time video scanning in POCUS but considering no ability to discriminate between small gallstones and small gallbladder polyps.

The US images in this study came from only two types of US machines that are not considered diverse enough. In actual practice, there are variabilities of the image color and resolution due to several types of US machines. Without varying the image quality, a large sample size is insufficient to develop a model with robust detection of unobserved images. Although we preprocessed the images post-production, this approach might not provide the variability as diverse as those in actual practice.

5. Conclusions

Using machine learning modules to identify abdominal diseases by abdominal US images, results of training using gallstones and cholecystitis showed acceptable detection performance and speed. Machine learning modules for various kinds of hepatobiliary diseases can help clinicians diagnose diseases by abdominal US and even provide remote medical care. In the future, computer-assisted systems may allow non-physician operators to help with initial diagnoses.

Declaration of Competing Interest

C.J.Y., H.J.Y., C.C.C., J.H.T., W.Y.K., W.C.C., Y.J.H., C.H.L., W.H.C., Y.T.L., H.S., and E.C.Y.S. have nothing to disclose.

CRediT authorship contribution statement

Chih-Jui Yu: Conceptualization, Methodology, Validation, Formal analysis, Investigation, Resources, Data curation, Writing – original draft, Project administration. **Hsing-Jung Yeh:** Investigation, Data curation, Writing – review & editing. **Chun-Chao Chang:** Conceptualization, Methodology, Resources, Writing – original draft, Supervision. **Jui-Hsiang Tang:** Investigation, Data curation, Writing – review & editing. **Wei-Yu Kao:** Investigation, Data curation, Writing – review & editing. **Wen-Chao Chen:** Investigation, Data curation, Writing – review & editing. **Yi-Jin Huang:** Software, Validation, Formal analysis, Resources, Writing – review & editing. **Chien-Hung Li:** Software, Validation, Formal analysis, Resources, Writing – review & editing. **Wei-Hao Chang:** Software, Validation, Formal analysis, Resources, Writing – review & editing. **Yun-Ting Lin:** Software, Validation, Formal analysis, Resources, Writing – review & editing. **Herdiantri Sufriyana:** Conceptualization, Formal analysis, Writing – original draft, Visualization. **Emily Chia-Yu Su:** Conceptualization, Methodology, Writing – original draft, Supervision, Funding acquisition.

Acknowledgment

This work was supported by the Ministry of Science and Technology (MOST) of Taiwan (Grant Nos. MOST109-2221-E-038-018 and MOST110-2628-E-038-001) and the Higher Education Sprout Project from the Ministry of Education (MOE) in Taiwan (Grant No. DP2-110-21121-01-A-13) to Emily Chia-Yu Su.

Appendix

A supplementary material is available in the supporting document/multimedia tab.

References

[1] National Center for Health Statistics, National hospital ambulatory medical survey: 2012 emergency care summary tables. https://www.cdc.gov/nchs/data/ahcd/nhamcs_emergency/2012_ed_web_tables.pdf., 2012 (accessed 13 April 2020).

[2] M.V. Revzin, L.M. Scoutt, J.G. Garner, C.L. Moore, Right upper quadrant pain: ultrasound first!, J. Ultrasound Med. 36 (2017) 1975–1985, doi:10.1002/jum.14274.

[3] R. Hilsden, R. Leeper, J. Koichopolos, J.D. Vandelinde, N. Parry, D. Thompson, F. Myslik, Point-of-care biliary ultrasound in the emergency department (BUSED): implications for surgical referral and emergency department wait times, Trauma Surg. Acute Care Open 3 (2018) e000164, doi:10.1136/tsaco-2018-000164.

[4] J. Pereira, G.A. Bass, D. Mariani, B.D. Dumbrava, A. Casamassima, A.R. da Silva, L. Pinheiro, I. Martinez-Casas, M. Zago, Surgeon-performed point-of-care ultrasound for acute cholecystitis: indications and limitations: a European society for trauma and emergency surgery (ESTES) consensus statement, Eur. J. Trauma Emerg. Surg. 46 (2020) 173–183, doi:10.1007/s00068-019-01197-z.
[5] O.R. Brook, R.A. Kane, G. Tyagi, B. Siewert, J.B. Kruskal, Lessons learned from quality assurance: errors in the diagnosis of acute cholecystitis on ultrasound and CT, AJR Am. J. Roentgenol. 196 (2011) 597–604, doi:10.2214/ajr.10.5170.
[6] Y. Matsui, S. Hirooka, M. Kotsuka, S. Yamaki, H. Kosaka, T. Yamamoto, S. Satoi, Prognosis in patients with gallbladder edema misdiagnosed as cholecystitis, JSLS 23 (2019), doi:10.4293/jsls.2019.00022.
[7] F. Lammert, K. Gurusamy, C.W. Ko, J.F. Miquel, N. Méndez-Sánchez, P. Portincasa, K.J. van Erpecum, C.J. van Laarhoven, D.Q. Wang, Gallstones, Nat. Rev. Dis. Primers 2 (2016) 16024, doi:10.1038/nrdp.2016.24.
[8] A. Di Ciaula, D.Q. Wang, P. Portincasa, An update on the pathogenesis of cholesterol gallstone disease, Curr. Opin. Gastroenterol. 34 (2018) 71–80, doi:10.1097/mog.0000000000000423.
[9] V. Halpin, Acute cholecystitis, BMJ Clin. Evid. 2014 (2014) https://pubmed.ncbi.nlm.nih.gov/PMC4140413.
[10] V. Soria Aledo, L. Galindo Iñíguez, D. Flores Funes, M. Carrasco Prats, J.L. Aguayo Albasini, Is cholecystectomy the treatment of choice for acute acalculous cholecystitis? A systematic review of the literature, Rev. Esp. Enferm. Dig. 109 (2017) 708–718, doi:10.17235/reed.2017.4902/2017.
[11] A. Thangavelu, S. Rosenbaum, D. Thangavelu, Timing of cholecystectomy in acute cholecystitis, J. Emerg. Med. 54 (2018) 892–897, doi:10.1016/j.jemermed.2018.02.045.
[12] P. Atkinson, J. Bowra, M. Lambert, H. Lamprecht, V. Noble, B. Jarman, International federation for emergency medicine point of care ultrasound curriculum, CJEM 17 (2015) 161–170, doi:10.1017/cem.2015.8.
[13] C. Gustafsson, A. McNicholas, A. Sondén, S. Törngren, H. Järnbert-Pettersson, A. Lindelius, Accuracy of surgeon-performed ultrasound in detecting gallstones: a validation study, World J. Surg. 40 (2016) 1688–1694, doi:10.1007/s00268-016-3468-3.
[14] B. Shekarchi, S.Z. Hejripour Rafsanjani, N. Shekar Riz Fomani, M. Chahardoli, Emergency department bedside ultrasonography for diagnosis of acute cholecystitis: a diagnostic accuracy study, Emergency 6 (2018) e11 (Tehran) https://pubmed.ncbi.nlm.nih.gov/PMC5827043 .
[15] D. Shi, J.H. Walline, X. Yu, J. Xu, P.P. Song, H. Zhu, Evaluating and assessing the prevalence of bedside ultrasound in emergency departments in China, J. Thorac. Dis. 10 (2018) 2685–2690, doi:10.21037/jtd.2018.04.88.
[16] L. Ratanaprasatporn, J.W. Uyeda, J.R. Wortman, I. Richardson, A.D. Sodickson, Multimodality imaging, including dual-energy CT, in the evaluation of gallbladder disease, Radiographics 38 (2018) 75–89, doi:10.1148/rg.2018170076.
[17] L.J. Brattain, B.A. Telfer, M. Dhyani, J.R. Grajo, A.E. Samir, Machine learning for medical ultrasound: status, methods, and future opportunities, Abdom. Radiol. (NY) 43 (2018) 786–799, doi:10.1007/s00261-018-1517-0.
[18] S. Liu, Y. Wang, X. Yang, B. Lei, L. Liu, S.X. Li, D. Ni, T. Wang, Deep learning in medical ultrasound analysis: a review, Engineering 5 (2019) 261–275, doi:10.1016/j.eng.2018.11.020.
[19] Y.J. Yang, C.S. Bang, Application of artificial intelligence in gastroenterology, World J. Gastroenterol. 25 (2019) 1666–1683, doi:10.3748/wjg.v25.i14.1666.
[20] S. Pang, S. Wang, A. Rodríguez-Patón, P. Li, X. Wang, An artificial intelligent diagnostic system on mobile android terminals for cholelithiasis by lightweight convolutional neural network, PLoS One 14 (2019) e0221720, doi:10.1371/journal.pone.0221720.
[21] J. Lian, Y. Ma, Y. Ma, B. Shi, J. Liu, Z. Yang, Y. Guo, Automatic gallbladder and gallstone regions segmentation in ultrasound image, Int. J. Comput. Assist. Radiol. Surg. 12 (2017) 553–568, doi:10.1007/s11548-016-1515-z.
[22] M.L. Giger, Machine learning in medical imaging, J. Am. Coll. Radiol. 15 (2018) 512–520, doi:10.1016/j.jacr.2017.12.028.
[23] K. Simonyan, A. Zisserman, Very deep convolutional networks for large-scale image recognition, arXiv 1409.1556 (2015).
[24] Szegedy C., Liu W., Jia Y., Sermanet P., Reed S., Anguelov D., Erhan D., Vanhoucke V., Rabinovich A., Going deeper with convolutions, 2015 IEEE Conference on Computer Vision and Pattern Recognition (CVPR), 2015, pp. 1-9.
[25] Szegedy C., Vanhoucke V., Ioffe S., Shlens J., Wojna Z., Rethinking the Inception architecture for computer vision, 2016 IEEE Conference on Computer Vision and Pattern Recognition (CVPR), 2016, pp. 2818-2826.
[26] Sifre L., Mallat S., Rigid-motion scattering for texture classification, arXiv 1403.1687 (2014). https://arxiv.org/abs/1403.1687
[27] Howard A.G., Zhu M., Chen B., Kalenichenko D., Wang W., Weyand T., Andreetto M., Adam H., MobileNets: efficient convolutional neural networks for mobile vision applications. arXiv 1704.04861 (2017). https://arxiv.org/abs/1704.04861
[28] Sandler M., Howard A., Zhu M., Zhmoginov A., Chen L.C., MobileNetV2: inverted residuals and linear bottlenecks, arXiv 1801.04381 (2018). https://arxiv.org/abs/1801.04381
[29] C. Datong, L. Minghui, J. Cheng, S. Yue, X. Dongbin, L. Yueming, Coronary calcium detection based on improved deep residual network in mimics, J. Med. Syst. 43 (2019) 119, doi:10.1007/s10916-019-1218-4.
[30] M.H.A. Nizar, C.K. Chan, A. Khalil, A.K.M. Yusof, K.W. Lai, Real-time detection of aortic valve in echocardiography using convolutional neural networks, Curr. Med. Imaging 16 (2020) 584–591, doi:10.2174/1573405615666190114151255.
[31] S. Pang, T. Ding, S. Qiao, F. Meng, S. Wang, P. Li, X. Wang, A novel YOLOv3-arch model for identifying cholelithiasis and classifying gallstones on CT images, PLoS One 14 (2019) e0217647, doi:10.1371/journal.pone.0217647.
[32] J.S. Dooley, K.S. Gurusamy, B.R. Davidson, Gallstones and benign biliary disease, in: Sherlock's Diseases of the Liver and Biliary System, Wiley-Blackwell, New Jersey, 2018, pp. 256–293.
[33] K. Khalili, S.R. Wilson, C.M. Rumack, D. Levin, The biliary tree and gallbladder, in: Diagnostic Ultrasound, Elsevier, Philadelphia, PA, 2018, pp. 165–209.
[34] F. Miura, K. Okamoto, T. Takada, S.M. Strasberg, H.J. Asbun, H.A. Pitt, H. Gomi, J.S. Solomkin, D. Schlossberg, H.S. Han, M.H. Kim, T.L. Hwang, M.F. Chen, W.S.W. Huang, S. Kiriyama, T. Itoi, O.J. Garden, K.H. Liau, A. Horiguchi, K.H. Liu, C.H. Su, D.J. Gouma, G. Belli, C. Dervenis, P. Jagannath, A.C.W. Chan, W.Y. Lau, I. Endo, K. Suzuki, Y.S. Yoon, E. de Santibañes, M.E. Giménez, E. Jonas, H. Singh, G. Honda, K. Asai, Y. Mori, K. Wada, R. Higuchi, M. Watanabe, T. Rikiyama, N. Sata, N. Kano, A. Umezawa, S. Mukai, H. Tokumura, J. Hata, K. Kozaka, Y. Iwashita, T. Hibi, M. Yokoe, T. Kimura, S. Kitano, M. Inomata, K. Hirata, Y. Sumiyama, K. Inui, M. Yamamoto, Tokyo guidelines 2018: initial management of acute biliary infection and flowchart for acute cholangitis, J. Hepato Biliary Pancreat. Sci. 25 (2018) 31–40, doi:10.1002/jhbp.509.
[35] R.C. Deo, Machine learning in medicine, Circulation 132 (2015) 1920–1930, doi:10.1161/circulationaha.115.001593.
[36] Lin T.Y., Maire M., Belongie S., Bourdev L., Girshick R., Hays J., Perona P., Ramanan D., Zitnick C.L., Dollár P., Microsoft COCO: common objects in context, arXiv 1405.0312 (2014). https://arxiv.org/abs/1405.0312
[37] O. Russakovsky, J. Deng, H. Su, J. Krause, S. Satheesh, S. Ma, Z. Huang, A. Karpathy, A. Khosla, M. Bernstein, A.C. Berg, L. Fei-Fei, ImageNet large scale visual recognition challenge, Int. J. Comput. Vis. 115 (2015) 211–252, doi:10.1007/s11263-015-0816-y.
[38] N. Antropova, B.Q. Huynh, M.L. Giger, A deep feature fusion methodology for breast cancer diagnosis demonstrated on three imaging modality datasets, Med. Phys. 44 (2017) 5162–5171, doi:10.1002/mp.12453.
[39] B.Q. Huynh, H. Li, M.L. Giger, Digital mammographic tumor classification using transfer learning from deep convolutional neural networks, J. Med. Imaging 3 (2016) 034501 (Bellingham), doi:10.1117/1.Jmi.3.3.034501.
[40] S. Koitka, A. Demircioglu, M.S. Kim, C.M. Friedrich, F. Nensa, Ossification area localization in pediatric hand radiographs using deep neural networks for object detection, PLoS One 13 (2018) e0207496, doi:10.1371/journal.pone.0207496.
[41] Y. Pang, T. Wang, R.M. Anwer, F.S. Khan, L. Shao, Efficient featurized image pyramid network for single shot detector, in: Proceedings of the IEEE/CVF Conference on Computer Vision and Pattern Recognition (CVPR), 2019, pp. 7328–7336.
[42] Liu W., Anguelov D., Erhan D., Szegedy C., Reed S., Fu C.Y., Berg A.C., SSD: single shot multibox detector, arXiv 1512.02325 (2016). https://arxiv.org/abs/1512.02325
[43] J. Huang, V. Rathod, C. Sun, M. Zhu, A. Korattikara, A. Fathi, I. Fischer, Z. Wojna, Y. Song, S. Guadarrama, K. Murphy, Speed/accuracy trade-offs for modern convolutional object detectors, in: Proceedings of the IEEE Conference on Computer Vision and Pattern Recognition (CVPR), 2017, pp. 3296–3297.
[44] T. Lin, P. Dollár, R. Girshick, K. He, B. Hariharan, S. Belongie, Feature pyramid networks for object detection, in: Proceedings of the IEEE Conference on Computer Vision and Pattern Recognition (CVPR), 2017, pp. 936–944.
[45] X. Zhang, F. Chen, T. Yu, J. An, Z. Huang, J. Liu, W. Hu, L. Wang, H. Duan, J. Si, Real-time gastric polyp detection using convolutional neural networks, PLoS One 14 (2019) e0214133, doi:10.1371/journal.pone.0214133.
[46] K. He, X. Zhang, S. Ren, J. Sun, Deep residual learning for image recognition, in: Proceedings of the IEEE Conference on Computer Vision and Pattern Recognition (CVPR), 2016, pp. 770–778.
[47] P.J. Carroll, D. Gibson, O. El-Faedy, C. Dunne, C. Coffey, A. Hannigan, S.R. Walsh, Surgeon-performed ultrasound at the bedside for the detection of appendicitis and gallstones: Systematic review and meta-analysis, Am. J. Surg. 205 (2013) 102–108, doi:10.1016/j.amjsurg.2012.02.017.
[48] J.J. Kiewiet, M.M. Leeuwenburgh, S. Bipat, P.M. Bossuyt, J. Stoker, M.A. Boermeester, A systematic review and meta-analysis of diagnostic performance of imaging in acute cholecystitis, Radiology 264 (2012) 708–720, doi:10.1148/radiol.12111561.